

Diagnosis of *Strongyloides stercoralis* Infection

Afzal A. Siddiqui^{1,2} and Steven L. Berk¹

¹Texas Tech University Health Sciences Center and ²Amarillo Veterans Affairs Healthcare System, Amarillo, Texas

Strongyloides stercoralis infects 30 million people in 70 countries. Infection usually results in asymptomatic chronic disease of the gut, which can remain undetected for decades. However, in patients receiving long-term corticosteroid therapy, hyperinfection can occur, resulting in high mortality rates (up to 87%). Strongyloidiasis is difficult to diagnose because the parasite load is low and the larval output is irregular. Results of a single stool examination by use of conventional techniques fail to detect larvae in up to 70% of cases. Several immunodiagnostic assays have been found ineffective in detecting disseminated infections and show extensive cross-reactivity with hookworms, filariae, and schistosomes. Although it is important to detect latent *S. stercoralis* infections before administering chemotherapy or before the onset of immunosuppression in patients at risk, a specific and sensitive diagnostic test is lacking. This review describes the clinical manifestations of strongyloidiasis, as well as various diagnostic tests and treatment strategies.

Strongyloidiasis is caused by 2 species of the intestinal nematode *Strongyloides*. The most common and globally distributed human pathogen of clinical importance is *Strongyloides stercoralis*. The other species, *Strongyloides fuelleborni*, is found sporadically in Africa and Papua New Guinea [1–3]. Strongyloidiasis affects anywhere from 30 to 100 million people worldwide [3, 4] and is endemic in Southeast Asia, Latin America, sub-Saharan Africa, and parts of the southeastern United States (tables 1 and 2) [2, 3, 8]. The unique ability of this nematode to replicate in the human host permits cycles of autoinfection, leading to chronic disease that can last for several decades [1–3].

S. stercoralis was first reported in 1876 in the stools of French soldiers on duty in Vietnam who had severe diarrhea, and the disease the organism produces was known for many years as Cochin-China diarrhea [1]. The elucidation of the complete life cycle (figure 1) occurred 50 years after the discovery of the worm. *S. stercoralis* has a complex life cycle in which parthenogenetic females (i.e., capable of reproducing without males) embedded in the intestinal mucosa lay embryonated eggs that hatch internally [1, 33]. The resultant first-stage larvae (L₁; rhabditiform larvae) are passed out in the feces and may de-

velop directly into second (L₂)–stage and third (L₃; filariform larvae)–stage larvae may develop through 4 free-living larval stages to become free-living adult males and females. The free-living adults reproduce sexually to produce L₁, which also develop to L₃. The L₃ of either cycle can penetrate the skin of the human host, pass through the circulation to the lungs, enter the airways, be swallowed, and finally reach the intestine, where they mature into adult egg-laying females (figure 1).

In autoinfection, larvae that have developed to the infective third stage within the gastrointestinal tract penetrate the intestinal mucosa and then migrate to the definitive site in the small intestine or to parenteral sites (e.g., lungs) [1, 34]. Some have argued that the pulmonary route is just one of the several possible pathways for the larvae to reach the duodenum [35]. In any event, this ability to establish a cycle of repeated endogenous reinfection within the host invariably results in chronic infection that can last for several decades; the current record appears to be 65 years [2].

Chronic infections with *S. stercoralis* can be clinically inapparent or can lead to cutaneous, gastrointestinal, or pulmonary symptoms [1, 2, 8, 36–38]. Skin involvement is characterized by a migratory, serpiginous, urticarial rash, termed larva currens [1, 2]. The larvae in many cases invade the skin in the perianal region and are extremely motile. The buttocks, groin, and trunk are more commonly affected by larva currens than the extremities and the head [2]. Gastrointestinal symptoms of strongyloidiasis include diarrhea, abdominal discomfort, nausea, and anorexia [1, 2, 8]. Abdominal bloating is the most common complaint

Received 9 March 2001; revised 25 April 2001; electronically published 5 September 2001.

Reprints or correspondence: Dr. Afzal A. Siddiqui, Texas Tech University Health Sciences Center, 1400 Wallace Blvd., Amarillo, Texas 79106 (siddiqui@cortex.ama.ttuhsu.edu).

Clinical Infectious Diseases 2001;33:1040–7

© 2001 by the Infectious Diseases Society of America. All rights reserved.
1058-4838/2001/3307-0018\$03.00

Table 1. Surveys of the prevalence of *Strongyloides stercoralis* in the United States.

Location	No. of specimens examined	Specimens positive for <i>S. stercoralis</i> , %	Reference
Harlan County, KY	125	4.0	[5]
Williamson, TN	221	1.0	[6]
Clay County, KY	561	3.0	[7]
Lexington, KY	3271	2.5	[7]
Johnson City, TN	575	4.0	[8]
Charleston, WV	4566	0.4	[9]
Baltimore, MD	51	3.9	[10]
Delaware, MD	339	0.6	[11]
New Orleans, LA	8458	0.4	[12]
Chicago, IL	358	1.7	[13]
New York, NY	10,072	1.0	[14]
Seattle, WA ^a	201	2.5	[15]

^a Among refugees from Asia.

[8]. When malabsorption is present, the radiographic findings are similar to those of tropical sprue, including increased diameter of the small intestinal lumen, generalized hypotonia, and edema [39]. The symptoms of pulmonary strongyloidiasis (hyperinfection) include cough and shortness of breath [1, 2, 8, 37–40]. Diagnosis is difficult because many patients have baseline pulmonary complaints [40, 41].

In hyperinfection and dissemination, complete disruption of the mucosal patterns, ulcerations, and paralytic ileus have been observed. In the presence of dissemination, pulmonary involvement may be heralded by bilateral edema and patchy, often rapidly changing infiltrates [1, 2, 8, 37–41]. Bacterial and fungal infections often occur in cases of hyperinfection because of the leakage of gut flora from a bowel damaged by moving larvae [1, 2]. The enteric bacteria are also carried by invasive *L*₃ larvae on their outer surfaces [1, 2]. This can result in septicemia, pneumonia, meningitis, and disseminated bacterial or fungal infection in many parts of the body, including the lungs [1, 2, 8, 36–38]. Massive secondary bacterial infections are frequently the immediate cause of death in patients with the hyperinfection syndrome.

The term “hyperinfection” is often used to denote autoinfection, a phenomenon in which the number of worms increases tremendously and the worms are detectable in extraintestinal regions, especially the lungs. The term “disseminated” is usually restricted to infections in which worms are found in ectopic sites (e.g., the brain). However, as Grove [1] points out, a simpler approach would be to recognize that there is a spectrum of severity of infection and that is hard to precisely quantify; it is simpler to categorize disease as “uncomplicated strongyloidiasis” or as “severe, complicated strongyloidiasis.”

The potential for severe disease is high in certain people at

high risk for acquiring strongyloidiasis [1, 2, 8, 36, 39]. The high-risk group includes the following: patients with altered cellular immunity, especially those receiving long-term steroid therapy; patients with lymphoma; kidney allograft recipients; travelers to areas of endemicity; and prisoners and other institutionalized people [1, 2, 8, 36, 39–43]. Most patients who develop hyperinfection syndrome are receiving corticosteroids, often for chronic obstructive pulmonary disease [8, 44, 45]. Hence, pulmonary strongyloidiasis may mimic an exacerbation of underlying chronic obstructive pulmonary disease [8, 40, 41]. Furthermore, in the past few years, a very limited number of patients with AIDS and extraintestinal strongyloidiasis have been reported [1, 2, 36–38]. Some conditions associated with HIV infection are known to predispose to hyperinfection syndrome, including inanition and the use of steroids. In fact, the list of immunosuppressive diseases associated with hyperinfection is unified by having corticosteroid treatment as a common denominator. However, it is now apparent that strongyloidiasis is not an important opportunistic infection associated with AIDS; the infection should still be searched for and promptly treated in HIV-infected patients who have a history of residence in and/or travel to areas of endemicity. On the other hand, strongyloidiasis appears to be a relevant opportunistic infection in patients infected with human T-lymphotropic virus 1 [1, 2, 36–38].

The diagnosis of strongyloidiasis should be suspected if there are clinical signs and symptoms, eosinophilia, or suggestive serologic findings [1–3, 8, 36]. Definitive diagnosis of strongyloidiasis is usually made on the basis of detection of larvae

Table 2. Recent data on *Strongyloides stercoralis* prevalence in some developing nations.

Location	No. of specimens examined	Specimens positive for <i>S. stercoralis</i> , %	Reference
Abidjan	1001	1.4	[16]
Argentina	36	83.3	[17]
Argentina	207	2.0	[18]
Brazil	200	2.5	[19]
Brazil	900	13.0	[20]
Ethiopia	1239	13.0	[21]
Guinea	800	6.4	[22]
Honduras	266	2.6	[23]
Israel	106	0.9	[24]
Kenya	230	4.0	[25]
Laos	669	19.0	[26]
Mexico	100	2.0	[27]
Nigeria	2008	25.1	[28]
Romania	231	6.9	[29]
Sierra Leone	1164	3.8	[30]
Sudan	275	3.3	[31]
Thailand	491	11.2	[32]

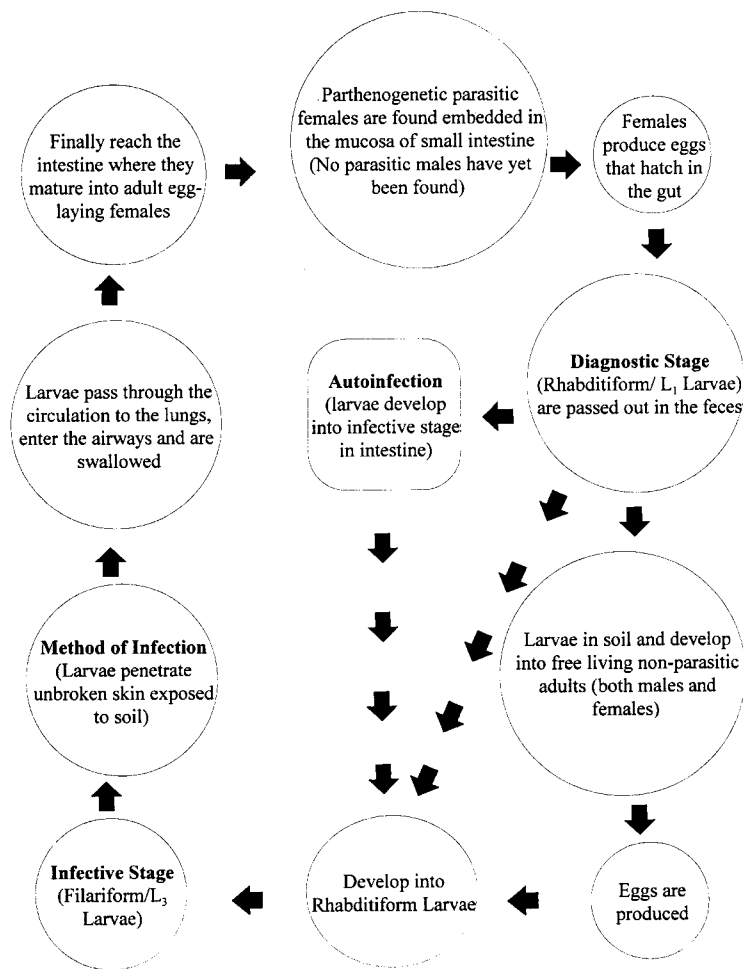


Figure 1. Life cycle of *Strongyloides stercoralis*

in the stool (figure 2A). However, in a majority of uncomplicated cases of strongyloidiasis, the intestinal worm load is often very low and the output of larvae is minimal [2]. Eosinophilia is usually the only indication to the presence of *S. stercoralis* infection, but it is mild (5%–15%) and nonspecific [1–3, 8, 36]. In more than two-thirds of cases, there are ≤ 25 larvae per gram of stool [2]. It has been shown that a single stool examination fails to detect larvae in up to 70% of cases. Repeated examinations of stool specimens improve the chances of finding parasites; in some studies, diagnostic sensitivity increases to 50% with 3 stool examinations and can approach 100% if 7 serial stool samples are examined [46, 47].

A number of techniques have been used to discern larvae in stool samples, including direct smear of feces in saline–Lugol iodine stain, Baermann concentration, formalin-ethyl acetate concentration, Harada-Mori filter paper culture, and nutrient agar plate cultures (figure 2) [48–50]. Concentrating the stool with formalin-ethyl acetate increases the yield, but dead individual larvae are more difficult to discern at low magnification. The Baermann method and the Harada-Mori filter paper cap-

italize on the ability of *S. stercoralis* to enter a free-living cycle of development. These methods are much more sensitive than single stool-smears, but they are rarely standard procedures in clinical parasitology laboratories [51]. In the Harada-Mori technique, filter paper containing fresh fecal material is placed in a test tube with water that continuously soaks the filter paper by capillary action. Incubation at 30°C provides conditions suitable for the development of larvae, which can migrate to either side of the filter paper [48–50]. In the Baermann procedure, stool is placed on mesh screen and a coarse fabric in a funnel that is filled with warm water and connected to a clamped tubing. After an hour of incubation, larvae crawl out of the fecal suspension and migrate into the warm water, from where they can be collected by centrifugation [48–50].

In the agar culture method, the stool sample is placed on a nutrient agar plate and incubated for at least 2 days [50, 52]. As the larvae crawl over the agar, they carry bacteria with them, creating visible tracks (figure 2C) [53]. Motile *S. stercoralis* larvae can also be seen with the aid of a dissecting microscope [54]. A comparative study that used >1300 stool samples and

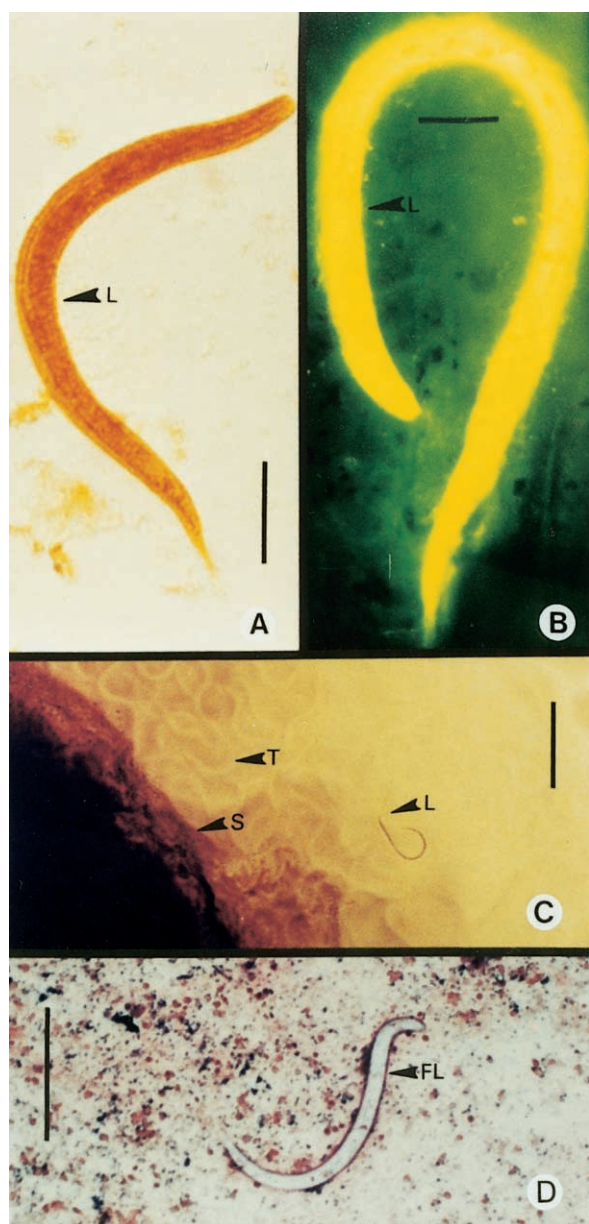


Figure 2. Different diagnostic staining and culture procedures for the detection of *Strongyloides stercoralis* larvae. **A**, Lugol iodine staining of the rhabditiform larva in stool. This is the most commonly used procedure in clinical microbiology laboratories. A single stool examination detects larvae in only 30% of cases of infection. Scale bar = 25 μm . **B**, Human fecal smear stained with auramine O, showing orange-yellow fluorescence of the rhabditiform larva under ultraviolet light. Routine acid-fast staining of sputum, other respiratory tract secretions (e.g., bronchial washings), and stool may also serve as a useful screening procedure. Scale bar = 25 μm . **C**, Agar plate culture method. Motile rhabditiform larvae and characteristic tracks or furrows, which are made by larvae on the agar around the stool sample. This diagnostic method is laborious and time-consuming (2–3 days) but is more sensitive than other procedures (e.g., wet mount analysis) for the detection of larvae in feces. Tracks are marked (arrows and T). S, stool sample on agar plate; L, larva or larvae. Scale bar = 250 μm . **D**, Gram stain demonstrating *S. stercoralis* filariform larvae (FL). Gram staining of a sputum sample is an excellent tool for diagnosing pulmonary strongyloidiasis. Scale bar = 250 μm .

4 different methods of stool examination (direct fecal smear, formalin-ethyl acetate concentration, Harada-Mori filter paper culture, and agar plate culture) found the agar plate culture method to be 96% sensitive [55]. In another study, the agar plate culture method was found to be 4.4 times more efficient than the direct smear procedure [23]. Although the agar plate method is laborious and time-consuming (requiring ~2–3 days), it is more sensitive than other procedures (e.g., wet mount analysis) for detection of larvae in feces [56]. As Grove [1] points out, “the balance of opinion probably favors the agar plate culture method but this is perhaps more expensive and complex” (p. 281).

Although some studies have reported that the examination of duodenal aspirate is very sensitive, this invasive method is recommended only for children, when it is necessary to rapidly demonstrate the presence of parasites, as in the case of an immunocompromised child who is suspected of having overwhelming infection [2, 39]. Microscopic examination of a single specimen of duodenal fluid was found to be more sensitive than wet mount analysis of stools samples for the detection of larvae [57]. This method identified 76% of patients; the parasite was found exclusively in duodenal fluid (and not in feces) in 67% of patients. The string test—a gelatin capsule containing a string that is swallowed by the patient and retrieved after a few hours—enjoyed a brief period of popularity, but currently it is used infrequently [58]. Also, in some cases, histological examination of duodenal or jejunal biopsy specimens may reveal *S. stercoralis* embedded in the mucosa [36, 39].

Detection of *S. stercoralis* larvae is usually easier in cases of hyperinfection, because large numbers of worms are involved in disseminated infections [2, 36, 39]. The larvae can be identified in wet preparations of sputum, bronchoalveolar lavage fluid, bronchial washings and brushings, lung biopsies, or examination of pleural fluid by means of Gram, Papanicolaou, or acid-fast (auramine O and Kinyoun) staining procedures [2, 37–41, 51, 59]. Findings of chest radiographs are usually variable; pulmonary infiltrates, when present, may be alveolar or interstitial, diffuse or focal, unilateral or bilateral [60]. Lung consolidation, occasional cavitation, and even abscess formation have also been reported [37–39]. The varying appearance of chest radiographs is due to different types of bacterial superinfection, particularly by gram-negative bacilli.

Because it is imperative to examine multiple stool samples to make a correct diagnosis, it is important to note that failure to detect larvae in a stool examination does not necessarily indicate the unequivocal absence of the infection [1, 2]. Hence, there is a great need for a highly specific and efficient serodiagnostic test for *S. stercoralis* that has the potential to be used even in multiple helminth infections. Several immunodiagnostic assays have been tested over the years, with limited success, including skin testing with larval extracts, indirect immunoflu-

orescence analysis of fixed larvae, radioallergosorbent testing for specific IgE, and gelatin particle agglutination [1, 2, 39, 61–63]. An ELISA test (*Strongyloides* antibody) for detecting the serum IgG against a crude extract of the filariform larvae of *S. stercoralis* is available only at specialized centers [1, 2, 39, 64–67]. The sensitivity and specificity of this ELISA test can be improved if the serum samples are preincubated with *Onchocerca* antigens before testing [64, 68].

The specificity question of this ELISA test has been thoroughly reviewed recently. Briefly, Genta [66] claimed that the ELISA was 88% sensitive, 99% specific, and had positive and negative predictive values of 97% and 95%, respectively. By use of state-of-the-art statistical models, in another study of Indochinese refugees in Canada, the ELISA was calculated to be 95% sensitive, 29% specific, and to have positive and negative predictive values of 30%, and 95%, respectively [69]. The difficulty in calculating diagnostic efficiency parameters can be attributed to the absence of a definitive gold standard for diagnosing *S. stercoralis* infection [70]. In population-based studies, it is widely believed that stool examination generally underestimates the prevalence, whereas serological examination generally overestimates it [1]. It has been argued that by use of a Bayesian approach, it is possible to make simultaneous inferences about the population prevalence and the sensitivity, specificity, and positive and negative predictive values of each diagnostic test [70]. Furthermore, demonstration of antibodies, even when correct, does not distinguish between past and current infection; and it is difficult in many cases to know whether or not low-level autoinfection is continuing [1]. This is mainly because antibody levels remain detectable for years after anthelmintic treatment [1, 2].

The *Strongyloides* antibody test shows cross-reactivity with other helminth infections, including filariasis, *Ascaris lumbricoides* infection, and acute schistosomiasis [65, 71], but for the general population in the United States, these are rarely included in the differential diagnosis of symptomatic strongyloidiasis [2]. However, this does not hold true with respect to veterans and international travelers, because these populations may have been exposed to cross-reactive antigens of other helminths while on trips outside the United States. Furthermore, helminths that contain cross-reactive antigens have the ability to persist long-term in the host and the tendency to produce circulating antibodies that can be detected for many years after exposure [72]. On a practical basis, this test is unlikely to be available for a wider use, because a constant supply of the *S. stercoralis* filariform larvae is needed to obtain the crude antigen preparation and an abundant supply of *Onchocerca* antigens is also required for presoaking of serum samples before performing an ELISA. The major value of serological examination is that it provides a screening test that, if positive, can stimulate a further search for the parasite [1, 2].

To improve the serodiagnosis of *S. stercoralis*, a number of proteins on the surface or in the excretory or secretory products of *S. stercoralis* infective larvae have been identified [1], some of which are shown to be immunoreactive with serum samples from infected humans [73, 74]. There is considerable variability among such serum samples; the number of reactive bands ranges from 1 to >18. However, the most prominent antigenic proteins of *S. stercoralis* appear to be of 28, 31, and 41 kDa in size [75, 76]. However, the specificity of these antigens has yet to be tested. Two *S. stercoralis* recombinant antigens, 5a and 12a, which show no cross-reactivity with serum samples from patients with filarial or nonstrongyloid intestinal nematode infections, have also been identified [77]. IgE and IgG4 antibodies against antigens 5a and 12a were also detected in patients infected with *Strongyloides* [77]. We have identified several bona fide antigens of *S. stercoralis* that are recognized by the host's immune system in natural human infections. Three of these antigens (P1, P4, and P5) exhibit no immunoreactivity with serum samples obtained from people infected with schistosomes, filarial parasites, hookworms, and *Onchocerca* [78].

Screening of a *S. stercoralis* complementary DNA library with affinity-purified antibodies against antigens P1, P4, and P5 has led to the identification of these antigens as oxoglutarate dehydrogenase, alkaline phosphatase, and isocitrate dehydrogenase [79, 80]. Studies are under way to express *S. stercoralis* oxoglutarate dehydrogenase, alkaline phosphatase, and isocitrate dehydrogenase in a baculovirus–insect cell system. The recombinant proteins generated will be used to develop antibody and antigen capture assays for the detection of *S. stercoralis*. It is expected that a test based on these 3 antigens will be extremely useful in detecting chronic, latent, and de novo infections of *S. stercoralis* and in monitoring the effectiveness of therapy. Such a test can also be used to detect *S. stercoralis* in multiple parasite infections.

Strongyloidiasis is a difficult infection to treat because, for many helminth infections, a treatment is considered sufficient if worm burden is below the level at which clinical disease develops [1, 2]. In *S. stercoralis*, however, only complete eradication of parasites removes the danger of potentially serious disease—that is, any truly effective anthelmintic must kill every autoinfective L₃ larvae, which are relatively resistant to chemical agents [1, 2]. Additionally, the poor sensitivity of diagnostic stool examination makes it even harder to determine the efficacy of treatment, because a true cure cannot be pronounced on the basis of negative findings of a follow-up stool examination alone. Thiabendazole (Mintezol; Merck & Company) has been the drug of choice for the treatment of strongyloidiasis, despite the associated gastrointestinal side effects and a high relapse rate [1, 56]. However, recent studies have shown that ivermectin (Stromectol; Merck & Company) is the best drug for the treatment of uncomplicated *S. stercoralis* infection [81].

It is well tolerated and has a higher cure rate than thiabendazole. Other drugs, such as mebendazole (Vermox; McNeil Consumer Healthcare) and albendazole, have had variable therapeutic efficacy [2]. Ivermectin has been found to be the most effective drug in treating disseminated strongyloidiasis [82] in patients with chronic intestinal disease, including children [83] and adults [84]. Recently, ivermectin has also been registered as the drug of choice in the World Health Organization's list of essential drugs for the treatment of *S. stercoralis* [85].

In summary, stool examination is currently the primary technique for the detection of *S. stercoralis* infection. If the diagnosis is strongly suspected and special techniques are not available, several specimens collected on different days should be examined. Generally, there are no distinctive clinical symptoms that suggest infection, although guaiac-positive stools and eosinophilia are common among infected patients. Almost all deaths due to helminths in the United States result from *S. stercoralis* hyperinfection [86, 87]. Mortality rates due to hyperinfection can be as high as 87% [88]. Because most of the fatal infections caused by *S. stercoralis* can be prevented by early detection and treatment of asymptomatic chronic infections, a comprehensive screening program that includes examination of eosinophilia should be applied to detect latent *S. stercoralis* infection before the start of chemotherapy, before immunosuppression, and before initiating steroid therapy for patients in endemic areas who are at risk.

Acknowledgment

We thank Dr. Steve Urban for reviewing the article.

References

- Grove DI. Human strongyloidiasis. *Adv Parasitol* **1996**; 38:251–309.
- Liu LX, Weller PF. Strongyloidiasis and other intestinal nematode infections. *Infect Dis Clin North Am* **1993**; 7:655–82.
- Genta RM. Global prevalence of strongyloidiasis: critical review with epidemiologic insights into the prevention of disseminated disease. *Rev Infect Dis* **1989**; 11:755–67.
- Jorgensen T, Montresor A, Savioli L. Effectively controlling strongyloidiasis [letter]. *Parasitol Today* **1996**; 12:164.
- Fulmer HS, Huempfer HR. Intestinal helminths in eastern Kentucky: a survey in three rural counties. *Am J Trop Med Hyg* **1965**; 14:269–75.
- Quinn RW. The epidemiology of intestinal parasites of importance in the United States. *South Med Bull* **1971**; 59:20–30.
- Walzer PD, Milder JE, Banwell JG, Kilgore G, Klein M, Parker R. Epidemiologic features of *Strongyloides stercoralis* infection in an endemic area of the United States. *Am J Trop Med Hyg* **1982**; 31:313–9.
- Berk SL, Verghese A, Alvarez S, Hall K, Smith B. Clinical and epidemiologic features of strongyloidiasis. A prospective study in rural Tennessee. *Arch Intern Med* **1987**; 147:1257–61.
- Kitchen LW, Tu KK, Kerns FT. *Strongyloides*-infected patients at Charleston area medical center, West Virginia, 1997–1998. *Clin Infect Dis* **2000**; 31:E5–6.
- Phillips SC, Mildvan D, William DC, Gelb AM, White MC. Sexual transmission of enteric protozoa and helminths in a venereal-disease-clinic population. *N Engl J Med* **1981**; 305:603–6.
- Unger BLP, Iscoe E, Cutler J, Bartlett JG. Intestinal parasites in a migrant farm worker population. *Arch Intern Med* **1986**; 146:513–5.
- Hubbard DW, Morgan PM, Yaeger RG, Unglaub WG, Hood MW, Willis RA. Intestinal parasite survey of kindergarten children in New Orleans. *Pediatr Res* **1974**; 8:652–8.
- Winsberg GR, Sonnenschein E, Dyer AR, Schnadig V, Bonilla E. Prevalence of intestinal parasites in Latino residents of Chicago. *Am J Epidemiol* **1975**; 102:526–32.
- Eveland LK, Kenney M, Yermakov V. Laboratory diagnosis of autoinfection in strongyloidiasis. *Am J Clin Pathol* **1975**; 63:421–5.
- Buchwald D, Lam M, Hooton TM. Prevalence of intestinal parasites and association with symptoms in Southeast Asian refugees. *J Clin Pharm Ther* **1995**; 20:271–5.
- Menan EL, Nebavi NG, Adjetey TA, Assavo NN, Kiki-Barro PC, Kone M. Profile of intestinal helminthiasis in school aged children in the city of Abidjan. *Bull Soc Pathol Exot* **1997**; 90:51–4.
- Taranto NJ, Bonomi de Filippi H, Orione O. Prevalence of *Strongyloides stercoralis* infection in childhood. Oran, Salta, Argentina. *Bol Chil Parasitol* **1993**; 48:49–51.
- Borda CE, Rea MJ, Rosa JR, Maidana C. Intestinal parasitism in San Cayetano, Corrientes, Argentina. *Bull Pan Am Health Organ* **1996**; 30:227–33.
- Cimerman S, Cimerman B, Lewi DS. Prevalence of intestinal parasitic infections in patients with acquired immunodeficiency syndrome in Brazil. *Int J Infect Dis* **1999**; 3:203–6.
- Machado ER, Costa-Cruz JM. *Strongyloides stercoralis* and other enteroparasites in children at Uberlandia City, state of Minas Gerais, Brazil. *Mem Inst Oswaldo Cruz* **1998**; 93:161–4.
- Fontanet AL, Sahlou T, Rinke de Wit T, et al. Epidemiology of infections with intestinal parasites and human immunodeficiency virus (HIV) among sugar-estate residents in Ethiopia. *Ann Trop Med Parasitol* **2000**; 94:269–78.
- Gyorkos TW, Camara B, Kokoskin E, Carabin H, Prouty R. Survey of parasitic prevalence in school-aged children in Guinea (1995). *Sante* **1996**; 6:377–81.
- de Kaminsky RG. Evaluation of three methods for laboratory diagnosis of *Strongyloides stercoralis* infection. *J Parasitol* **1993**; 79:277–80.
- Huimer D, Symon K, Groskopf I, et al. Seroepidemiologic study of toxocariasis and strongyloidiasis in institutionalized mentally retarded adults. *Am J Trop Med Hyg* **1992**; 46:278–81.
- Joyce T, McGuigan KG, Elmore-Meegan M, Conroy RM. Prevalence of enteropathogens in stools of rural Maasai children under five years of age in the Maasailand region of the Kenyan Rift Valley. *East Afr Med J* **1996**; 73:59–62.
- Vannachone B, Kobayashi J, Nambanya S, Manivong K, Inthakone S, Sato Y. An epidemiological survey on intestinal parasite infection in Khammouane Province, Lao PDR, with special reference to *Strongyloides* infection. *Southeast Asian J Trop Med Public Health* **1998**; 29:717–22.
- Guarner J, Matilde-Nava T, Villasenor-Flores R, Sanchez-Mejorada G. Frequency of intestinal parasites in adult cancer patients in Mexico. *Arch Med Res* **1997**; 28:219–22.
- Agi PI. Comparative helminth infections of man in two rural communities of the Niger Delta, Nigeria. *West Afr J Med* **1997**; 16:232–6.
- Panaiteanu D, Capraru T, Bugarin V. Study of the incidence of intestinal and systemic parasitoses in a group of children with handicaps. *Roum Arch Microbiol Immunol* **1995**; 54:65–74.
- Gbakima AA, Sahr F. Intestinal parasitic infections among rural farming communities in eastern Sierra Leone. *Afr J Med Med Sci* **1995**; 24:195–200.
- Magambo JK, Zeyhle E, Wachira TM. Prevalence of intestinal parasites among children in southern Sudan. *East Afr Med J* **1998**; 75:288–90.
- Kasuya S, Khamboonruang C, Amano K, et al. Intestinal parasitic infections among schoolchildren in Chiang Mai, northern Thailand: an analysis of the present situation. *J Trop Med Hyg* **1989**; 92:360–4.
- Mansfield LS, Niamatali S, Bhopale V, et al. *Strongyloides stercoralis*:

- maintenance of exceedingly chronic infections. *Am J Trop Med Hyg* **1996**;55:617–24.
34. Mansfield LS, Schad GA. Ivermectin treatment of naturally acquired and experimentally induced *Strongyloides stercoralis* infections in dogs. *J Am Vet Med Assoc* **1992**;201:726–30.
 35. Schad GA, Aikens LM, Smith G. *Strongyloides stercoralis*: is there a canonical migratory route through the host? *J Parasitol* **1989**;75:740–9.
 36. Heyworth MF. Parasitic diseases in immunocompromised hosts. Cryptosporidiosis, isosporiasis, and strongyloidiasis. *Gastroenterol Clin North Am* **1996**;25:691–707.
 37. Woodring JH, Halfhill H, Reed JC. Pulmonary strongyloidiasis: clinical and imaging features. *AJR Am J Roentgenol* **1994**;162:537–42.
 38. Woodring JH, Halfhill H, Berger R, Reed JC, Moser N. Clinical and imaging features of pulmonary strongyloidiasis. *South Med J* **1996**;89:10–9.
 39. Genta RM. *Strongyloides stercoralis*. In: Blaser MJ, Smith PD, Ravdin JI, Greenberg HB, Guerrant RL, eds. *Infections of the gastrointestinal tract*. New York: Raven Press, **1995**:1197–207.
 40. Berk SL, Verghese A. Parasitic pneumonia. *Semin Respir Infect* **1988**;3:172–8.
 41. Smith B, Verghese A, Guterrez C, Dralle W, Berk SL. Pulmonary strongyloidiasis. Diagnosis by sputum Gram stain. *Am J Med* **1985**;79:663–6.
 42. Rudrapatna JS, Kumar V, Sridhar H. Intestinal parasitic infections in patients with malignancy. *J Diarrhoeal Dis Res* **1997**;15:71–4.
 43. Palau LA, Pankey GA. *Strongyloides* hyperinfection in renal transplant recipient receiving cyclosporine: possible *Strongyloides stercoralis* transmission by kidney transplant. *Am J Trop Med Hyg* **1997**;57:413–5.
 44. Wehner JH, Kirsch CM. Pulmonary manifestations of strongyloidiasis. *Semin Respir Infect* **1997**;12:122–9.
 45. Igra-Siegmán Y, Kapila R, Sen P, Kaminski ZC, Louria DB. Syndrome of hyperinfection with *Strongyloides stercoralis*. *Rev Infect Dis* **1981**;3:397–407.
 46. Nielsen PB, Mojon M. Improved diagnosis of strongyloides stercoralis by seven consecutive stool specimens. *Zentralbl Bakteriol Mikrobiol Hyg [A]* **1987**;263:616–8.
 47. Pelletier LL. Chronic strongyloidiasis in World War II Far East ex-prisoners of war. *Am J Trop Med Hyg* **1984**;33:55–61.
 48. Garcia LS, Bruckner DA. *Diagnostic medical parasitology*. Washington, DC: American Society for Microbiology, **1993**.
 49. Leventhal R, Cheadle RF. *Medical parasitology: a self-instructional text*. Philadelphia: FA Davis, **1989**.
 50. Gutierrez Y. *Diagnostic pathology of parasitic infections with clinical correlations*. 2d ed. Oxford: Oxford University Press, **2000**.
 51. Kemp L, Hawley T. Clinical pathology rounds. Strongyloidiasis in a hyperinfected patient. *Lab Med* **1996**;27:237–40.
 52. Arakaki T, Iwanaga M, Kinjo F, Saito A, Asato R, Ikeshiro T. Efficacy of agar-plate culture in detection of *Strongyloides stercoralis* infection. *J Parasitol* **1990**;76:425–8.
 53. Panosian KJ, Marone P, Edberg SC. Elucidation of *Strongyloides stercoralis* by bacterial-colony displacement. *J Clin Microbiol* **1986**;24:86–8.
 54. Salazar SA, Gutierrez C, Berk SL. Value of the agar plate method for the diagnosis of intestinal strongyloidiasis. *Diagn Microbiol Infect Dis* **1995**;23:141–5.
 55. Sato Y, Kobayashi J, Toma H, Shiroma Y. Efficacy of stool examination for detection of *Strongyloides* infection. *Am J Trop Med Hyg* **1995**;53:248–50.
 56. Zaha O, Hirata T, Kinjo F, Saito A. Strongyloidiasis—progress in diagnosis and treatment. *Intern Med* **2000**;39:695–700.
 57. Goka AK, Rolston DD, Mathan VI, Farthing MJ. Diagnosis of *Strongyloides* and hookworm infections: comparison of faecal and duodenal fluid microscopy. *Trans R Soc Trop Med Hyg* **1990**;84:829–31.
 58. Beal CB, Viens P, Grant RG, Hughes JM. A new technique for sampling duodenal contents: demonstration of upper small-bowel pathogens. *Am J Trop Med Hyg* **1970**;19:349–52.
 59. Siddiqui AA, Guterrez C, Berk SL. Diagnosis of *Strongyloides stercoralis* by acid-fast staining. *J Helminthol* **1999**;73:187–8.
 60. Ansari TM, Couch L, Idell S. *Strongyloides*-induced lung disease. *Emerg Med* **1997**;127–36.
 61. Neva FA. Biology and immunology of human strongyloidiasis. *J Infect Dis* **1986**;153:397–406.
 62. Sato Y, Otsuru M, Takara M, Shiroma Y. Intradermal reactions in strongyloidiasis. *Int J Parasitol* **1986**;16:87–91.
 63. Sato Y, Toma H, Kiyuna S, Shiroma Y. Gelatin particle indirect agglutination test for mass examination for strongyloidiasis. *Trans R Soc Trop Med Hyg* **1991**;85:515–8.
 64. Lindo JF, Conway DJ, Atkins NS, Bianco AE, Robinson RD, Bundy DA. Prospective evaluation of enzyme-linked immunosorbent assay and immunoblot methods for the diagnosis of endemic *Strongyloides stercoralis* infection. *Am J Trop Med Hyg* **1994**;51:175–9.
 65. Gam AA, Neva FA, Krotoski WA. Comparative sensitivity and specificity of ELISA and IHA for serodiagnosis of strongyloidiasis with larval antigens. *Am J Trop Med Hyg* **1987**;37:157–61.
 66. Genta RM. Predictive value of an enzyme-linked immunosorbent assay (ELISA) for the serodiagnosis of strongyloidiasis. *Am J Clin Pathol* **1988**;89:391–4.
 67. Sato Y, Kobayashi J, Shiroma Y. Serodiagnosis of strongyloidiasis. The application and significance. *Rev Inst Med Trop Sao Paulo* **1995**;37:35–41.
 68. Conway DJ, Atkins NS, Lillywhite JE, et al. Immunodiagnosis of *Strongyloides stercoralis* infection: a method for increasing the specificity of the indirect ELISA. *Trans R Soc Trop Med Hyg* **1993**;87:173–6.
 69. Gyorkos TW, Genta RM, Viens P, MacLean JD. Seroepidemiology of *Strongyloides* infection in the Southeast Asian refugee population in Canada. *Am J Epidemiol* **1990**;132:257–64.
 70. Joseph L, Gyorkos TW, Coupal L. Bayesian estimation of disease prevalence and the parameters of diagnostic tests in the absence of a gold standard. *Am J Epidemiol* **1995**;141:263–72.
 71. Lindo JF, Atkins NS, Lee MG, Robinson RD, Bundy DA. Parasite-specific serum IgG following successful treatment of endemic strongyloidiasis using ivermectin. *Trans R Soc Trop Med Hyg* **1996**;90:702–3.
 72. Maizels RM, Bundy DAP, Selkirk ME, Smith DF, Anderson RM. Immunological modulations and evasion by helminth parasites in human populations. *Nature* **1993**;365:797–805.
 73. Brindley PJ, Gam AA, Pearce EJ, Poindexter RW, Neva FA. Antigens from the surface and excretions/secretions of the filariform larva of *Strongyloides stercoralis*. *Mol Biochem Parasitol* **1988**;28:171–80.
 74. Sato Y, Inoue F, Matsuyama R, Shiroma Y. Immunoblot analysis of antibodies in human strongyloidiasis. *Trans R Soc Trop Med Hyg* **1990**;84:403–6.
 75. Conway DJ, Bailey JW, Lindo JF, Robinson RD, Bundy DA, Bianco AE. Serum IgG reactivity with 41-, 31-, and 28-kDa larval proteins of *Strongyloides stercoralis* in individuals with strongyloidiasis. *J Infect Dis* **1993**;168:784–7.
 76. Conway DJ, Lindo JF, Robinson RD, Bundy DA, Bianco AE. *Strongyloides stercoralis*: characterization of immunodiagnostic larval antigens. *Exp Parasitol* **1994**;79:99–105.
 77. Ramachandran S, Thompson RW, Gam AA, Neva FA. Recombinant cDNA clones for immunodiagnosis of strongyloidiasis. *J Infect Dis* **1998**;177:196–203.
 78. Siddiqui AA, Koenig NM, Sinensky M, Berk SL. *Strongyloides stercoralis*: identification of antigens in natural human infections from endemic areas of the United States. *Parasitol Res* **1997**;83:655–8.
 79. Siddiqui AA, Stanley CS, Berk SL. Cloning and expression of isocitrate lyase from human round worm *Strongyloides stercoralis*. *Parasite* **2000**;7:233–6.
 80. Siddiqui AA, Stanley CS, Berk SL. A cDNA encoding the highly immunodominant antigen of *Strongyloides stercoralis*: gamma-subunit of isocitrate dehydrogenase (NAD⁺). *Parasitol Res* **2000**;86:279–83.
 81. Salazar SA, Berk SH, Howe D, Berk SL. Ivermectin vs thiabendazole in the treatment of strongyloidiasis. *Infect Med* **1994**;50–59.

82. Daubenton JD, Buys HA, Hartley PS. Disseminated strongyloidiasis in a child with lymphoblastic lymphoma. *J Pediatr Hematol Oncol* **1998**; 20:260–3.
83. Adenusi AA. Cure by ivermectin of a chronic, persistent, intestinal strongyloidosis. *Acta Trop* **1997**; 66:163–7.
84. Marti H, Haji HJ, Savioli L, et al. A comparative trial of a single-dose ivermectin versus three days of albendazole for treatment of *Strongyloides stercoralis* and other soil-transmitted helminth infections in children. *Am J Trop Med Hyg* **1996**; 55:477–81.
85. Albonico M, Crompton DW, Savioli L. Control strategies for human intestinal nematode infections. *Adv Parasitol* **1999**; 42:277–341.
86. Muennig P, Pallin D, Sell RL, Chan M. The cost effectiveness of strategies for the treatment of intestinal parasites in immigrants. *N Engl J Med* **1999**; 340:773–9.
87. Mitre E. Treatment of intestinal parasites in immigrants. *N Engl J Med* **1999**; 341:377–8.
88. Link K, Orenstein R. Bacterial complications of strongyloidiasis: *Streptococcus bovis* meningitis. *South Med J* **1999**; 92:728–31.